

## Gastrointestinal Stromal Tumor A Clinicopathological Study.

Anita B. Sajjanar, MD\*<sup>1</sup>, U S Dinesh, MD<sup>\$1</sup>, Anshul Kumar, MD\*<sup>2</sup>, Ravikala Rao, MD<sup>\$1</sup>

\*Assistant Professor, <sup>\$</sup>Professor

<sup>1</sup>Department Of Pathology, Shri Dharmasthala Manjunatheshwara College Of Medical Sciences And Hospital, Sattur, Dharwad, Karnataka, India.

<sup>2</sup>Department Of Pathology, K D Medical College Hospital And Research Centre, Mathura, India.

---

### Abstract:

**Background** - Gastrointestinal stromal tumours (GIST) are KIT-expressing signal driven mesenchymal tumours of the gastrointestinal (GI) tract. Currently the diagnosis of these tumours is based on study of histomorphologic features and Immunohistochemical (IHC) demonstration of CD117 which is essential to distinguish it from other mesenchymal tumours of GI tract. Surgical resection followed by adjuvant treatment of Tyrosine kinase inhibitor has got encouraging outcomes even in chemotherapy-resistant advanced GIST.

**Aim**- To present the clinical, radiological, histopathological and IHC features in seventeen cases.

**Material and Methods**- Medical records of all seventeen patients were reviewed for their clinical presentation, laboratory investigations, radiological, histopathological and IHC findings in detail.

**Results** - In a series of 17 patients, eight were males and nine females. Mean age was 49 years with pain abdomen as the commonest symptom of presentation. Three of the 17 patients underwent only core needle biopsy, while fourteen operated specimens were available for gross, microscopic and IHC analysis. Small intestine was the commonest site of occurrence of the tumor. IHC marker CD 117 was positive in all the cases while CD 34 in three cases only.

**Conclusion**- GIST is a rare tumor. Histopathology and IHC are essential and together help to distinguish it from other mesenchymal tumours of the GI tracts. In this study of series of 17 cases of GISTs collected over a period of 10 year, small intestine was the commonest site.

**Keywords:** Gastrointestinal stromal tumours, IHC, Tyrosine kinase inhibitor.

---

### I. Introduction

Gastrointestinal stromal tumours (GIST) are KIT-expressing signal driven mesenchymal tumours of the gastrointestinal (GI) tract.<sup>1</sup> Earlier these tumours were labelled as leiomyomas, leiomyosarcoma and leiomyoblastomas.<sup>2</sup> Mazur and Clark in 1983, were the first to coin the term GIST. It is used for those tumours which encompassed non-epithelial origin neoplasms of gastrointestinal tract, which lacked the immunohistochemical features of Schwann cells and did not have the ultra-structure of smooth muscle cells.<sup>3</sup> The tumor cells are derived from the interstitial cells of Cajal, which functions as gut pacemaker. They create the basal electrical rhythm leading to peristalsis in GI tract.<sup>4</sup>

Nearly 90% of GISTs occur in adults. The incidence among the sexes is the same, however with a slight predominance for the male sex.<sup>5</sup> Stomach is the commonest site of their occurrence (60%-70%), followed by the small intestine and rarely the colon, rectum, oesophagus and appendix. Extra-intestinal sites include omentum, mesentery, and the retroperitoneum.<sup>6</sup> Clinical presentation may vary from acute and chronic gastrointestinal bleeding, abdominal pain, abdominal mass, anorexia and intestinal obstruction.<sup>7</sup>

Complete surgical resection without tumor spillage is the gold standard of management,<sup>8</sup> followed by adjuvant treatment by Tyrosine kinase inhibitor Imatinib mesylate, which has got good outcomes in chemotherapy-resistant advanced GIST.<sup>9,10</sup> Hence prompt histopathological diagnosis using Immunohistochemical (IHC) markers is imperative. Currently the diagnosis of these tumours is based on study of morphologic features, IHC demonstration of CD117 and other markers which is essential and also helpful to distinguish it from other mesenchymal tumours of the gastrointestinal tract.<sup>6</sup>

We present our experience in a series of 17 cases. Their clinical, radiological, histopathological and IHC features are discussed in detail.

### II. Material And Methods

At a tertiary care teaching institute seventeen patients presenting with GIST were studied retrospectively over a period of ten years. Medical records of all the patients were reviewed for their clinical presentation. The laboratory investigations and radiological findings from ultrasonography (USG), computed tomography (CT) and magnetic resonance imaging (MRI) findings were collected and analyzed. Location of

tumor, type of surgical resection and treatment outcomes were recorded. Gross and histopathological findings of all the cases were carefully evaluated. IHC stains were performed on formalin-fixed, paraffin-embedded tissue of the tumours using standard protocols. The antibodies used for the immunohistochemical stains were CD117, CD34. The main prognostic factors such as size, mitotic index and metastasis were observed and analyzed using Fletcher's classification.<sup>11</sup>

### III. Results

There were eight males and nine females. Age of the patients ranged between 20 and 70 years with mean age of 49 years. **(Figure-1)** The most common presentation was pain abdomen (11 of 17 patients) followed by mass per abdomen (five), melena (four), constipation (three) and others (four cases). **(Figure- 2)** All the patients underwent USG, CT scan **(Figure -3)** and MRI scan which in majority patients showed well defined lobulated mass.

Three of the 17 patients underwent only core needle biopsy, hence gross examination of the specimen was not available, while fourteen operated specimens were analyzed for gross, microscopic histopathology and IHC analysis. 35.7% of the tumours measured 1-5 cm while only one tumor was more than 20 cm. **(TABLE- 1)** Small intestine was the commonest site of occurrence in our series which accounted for 41% followed by stomach (17.6%) and mesentery (17%).

Grossly 10 (71.1%) of the tumours appeared well circumscribed, grey white to grey brown globular mass; three (21.4%) specimens were showing irregular, grey white lesions and one case showed a polypoidal lesion. **(Figure-4)** The cut surface revealed varying patterns from grey white to tan brown colour with areas of haemorrhage and necrosis in 11/14 cases while rest were showing grey white to tan brown homogenous. **(Figure-5)**

they showed varying patterns including spindle, epithelioid and mixed morphology. Fourteen of 17 cases were showing spindle cell variant **(Figure- 6)** features while epithelioid and mixed variant were seen in two and one cases respectively. **(Figure-7)** Malignant tumours showed mitotic figures of  $> 5/50$  hpf.

IHC marker for CD 117 **(Figure 8A)** was positive in all the cases while CD 34 in three cases only **(Figure 8B)**. All 17 patients received Imatinib therapy and follow up done for 1 to 2 years. All the patients were recurrence free for this period.

### IV. Discussion

Stromal tumours encompass majority of primary non-epithelial neoplasms of stomach.<sup>12</sup> However, they can also involve the small intestine and extra intestinal portions of GI tract. Collectively, they as a group are called GIST. As a result of pronounced variability in their differentiation pathways, GISTs exhibit considerable degree of confusion in their interpretation.

Gastrointestinal stromal tumours are rare tumours with an estimated incidence of 1.5/100000 per year.<sup>13</sup> At our institute over a period of 10 years 3,612 GI specimens were received for histopathological examination, out of which 17 were proven to be GIST, an incidence of 0.47%. In a series by Nilsson et al and Goettsch WG et al nearly 10% were detected at autopsy and 20% of the tumours were detected incidentally during either endoscopy, imaging of the abdomen, or at surgery for some other conditions<sup>14</sup>.

They can vary in their malignant potential, from small tumours with excellent outcome to aggressive sarcomas. Forty three percent of the patients in present study were falling in high risk category. The proportion of overtly malignant or high-risk GISTs is 20–35% of all the GISTs<sup>14,15</sup>

Previously described as tumours of the gastrointestinal system with mesenchymal character, the origin of GIST could not be identified and the tumor was not responsive to established chemotherapeutic treatment. However, with the help of IHC it is now possible to pin point the origin of these tumours.<sup>16,17</sup> Newer modalities of diagnosis and better understanding of tumor biology has helped to develop molecularly targeted drug therapy. Therefore, it has now become essential to study the incidence, prevalence and the understanding of clinical behaviour of GIST. This can help in better management of GIST.<sup>14</sup>

Present study showed wide range of age of presentation of GIST, age ranging from 20 to 70 years with mean age of 49 years and median of 45 years, while the study by Miettinen et al shows age ranging from 13-94 years with median of 59 years.<sup>18</sup>

They are known to occur anywhere in the GI tract.<sup>3,18</sup> Stomach is the commonest site (60% to 70%) followed by small intestine (25% to 35%), and less commonly in other intestinal sites such as the colon, rectum (5%), and oesophagus. It can be a small benign tumor or frank sarcomas at any of these above mentioned sites. The commonest site of GIST in our study was small intestine 41% (7cases) followed by stomach 17.6% (3cases), mesentery 11.7 % (3cases), rectum 5.8 % (2case), esophagus and one from Meckel's diverticulum which is a rare site of occurrence. Benign GISTs outnumber malignant variety in the stomach, where as the small intestine harbour mostly malignant type of GISTs.<sup>19</sup> In the present study, four of seven cases involving

intestine were malignant while only one involving stomach was malignant, which was consistent with other studies. Therefore site of occurrence of the tumor has been one of the important prognostic factor.

Clinical signs and symptoms were related to presence of mass or bleeding. Abdominal pain 64.7 % (11) was most common symptom followed by per rectal bleeding/melena in 23.5% (4). However most of the patients also had vague symptoms like constipation, painful defecation, nausea, and vomiting, abdominal discomfort and weight loss. These clinical features were correlating with the study done by Kumar R N et al <sup>21</sup>

In the present study 71.1% (10/14 cases) the gross appearance of the tumor was globular, well circumscribed and grey white to grey brown in colour. In three it had irregular surface, grey white appearance while only one had polypoidal nature. Study done by Kumar RN showed 50% of GIST presenting as mass lesion followed by 31% polypoidal lesion. In eleven of fourteen cases the cut surface of tumor were tan brown with secondary changes like haemorrhage, necrosis and cystic changes correlating with study done by Kumar RN<sup>21</sup>

Histologically the most common variant was spindle cell 82% (14 cases) followed by epitheloid variant 12% (2cases) and one (0.6%) was of mixed type. Our study was correlating with the study done by Miettinen et al which showed the similar finding with spindle cell variant (86%), epitheloid variant 5% and mixed pattern in 9% cases of GIST.<sup>22</sup>

Many authors have accepted tumor size and mitotic figure as the reliable parameters for determining prognosis.<sup>18,22</sup> A smaller tumor diameter (< 2 cm) has lesser risk of progressive disease anywhere whereas a tumor greater than 5cm located in small intestine and larger than 10 cm in stomach were reported to have poor in prognosis by a few authors.<sup>17,21</sup> In our series out of 17 patients tumor size was assessed in 14 operated specimens while three had undergone core biopsies in which size of the tumor could not be assessed. Five out of 14 cases, the size of lesion was ranging between 1-5 cm. While in only one case the tumor size was exceeding 20cms

According to NIH <sup>22</sup> and AFIP<sup>24</sup> criteria based on tumor location, size and mitoses, six (43%) of our 17 GIST were classified in the high risk group where malignant behaviour is expected. A study presented at the 21st European Pathology Congress reported the classification of 1008 GIST cases gathered from 29 centres in Turkey as high risk in 54%, moderate in 19%, low risk in 21% and very low risk in 6% <sup>23</sup> (**Table -2**) Our study has correlated with above study.

Immunohistochemical studies are required in addition to routine HE examinations for the correct diagnosis of these special tumours that show similar morphological appearance and location to other mesenchymal tumours but have a totally different prognosis and treatment. <sup>25</sup> GISTs originate from the interstitial cells of Cajal, which are CD117 marker positive. The positivity of CD117 may be variable at the rate of 65-100% as shown in several studies. <sup>26</sup>

Earlier to identification of CD117, CD34 was considered to be the most valuable marker. Its positivity in GISTs varies between 40 and 82% <sup>27</sup> In our series 17% showed positivity for CD34.

Aggressive complete surgical resection can achieve prolongation of life and may be a potential cure for patients with GISTs.<sup>28</sup> A follow up treatment with KIT tyrosine kinase inhibitor, STI-571 (Imatinib) has shown promising results in the treatment of GISTs.<sup>6</sup> It has also proved effective in metastatic GISTs. Same drug is under investigation as a neoadjuvant and adjuvant therapy.<sup>29</sup> In the present study all the patients were followed up for not less than 2 years, none of them had recurrence.

## **V. Conclusion**

Gastrointestinal stromal tumor is a rare tumor. Though radiological findings can give clue to the diagnosis, histopathological features with IHC are confirmatory in diagnosing these lesions. IHC is essential and helps to distinguish it from other mesenchymal tumours of the gastrointestinal tracts for their better management.

We presented study of series of 17 cases of GISTs collected over a period of ten years, out of which majority were of high grade potential and small intestine being commonest site unlike other studies. CD 117 was positive in all and we presume that these patients are good candidates for Imatinib therapy.

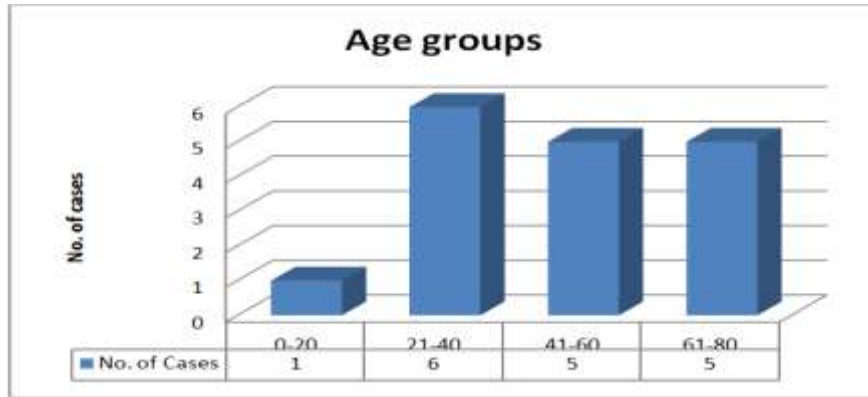


Figure 1. Graph showing distribution of cases in various age groups.

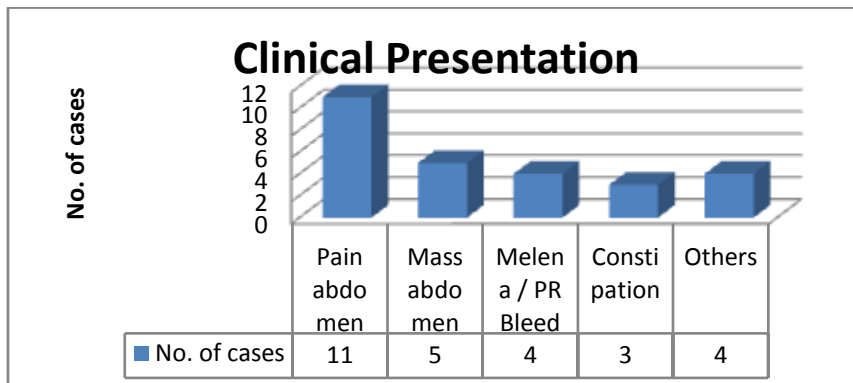


Figure 2. Clinical presentation with various signs and symptoms of the cases.

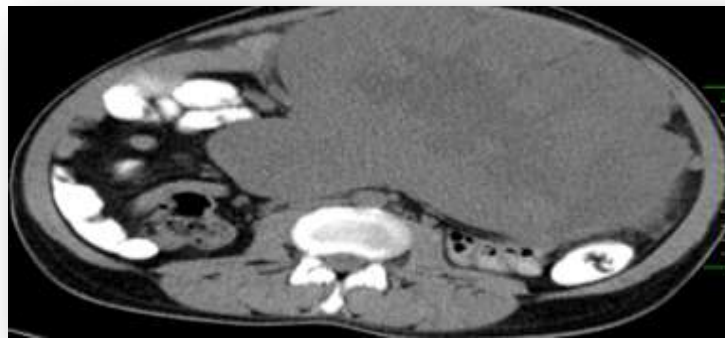
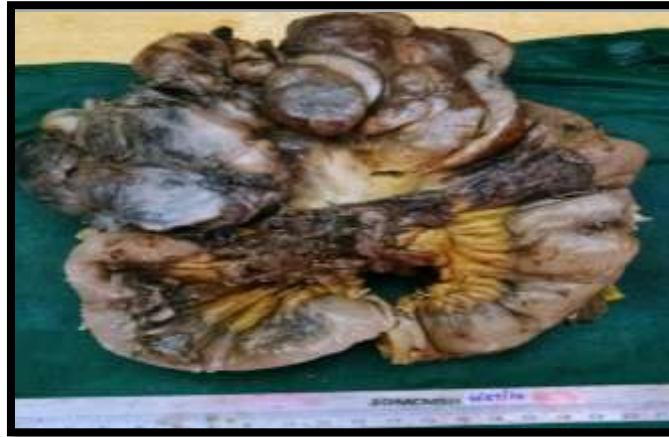
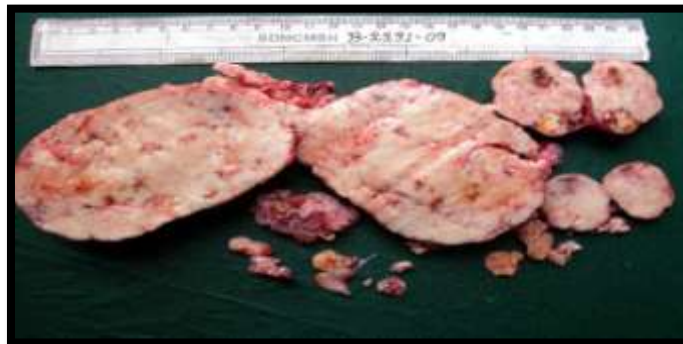
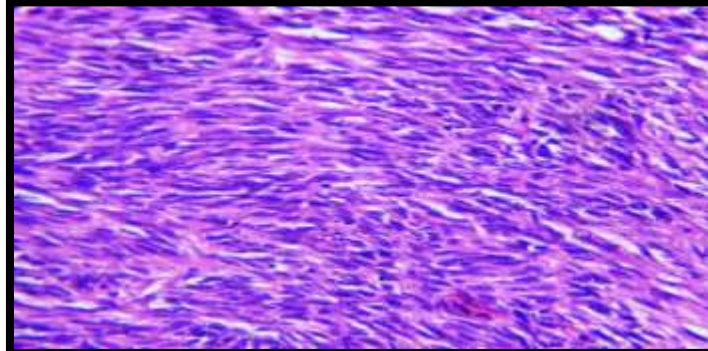
Figure.3- MDCT Scan – Abdomen and pelvis showing large well defined, lobulated, mixed density, heterogeneously enhancing mass in the mesentery.



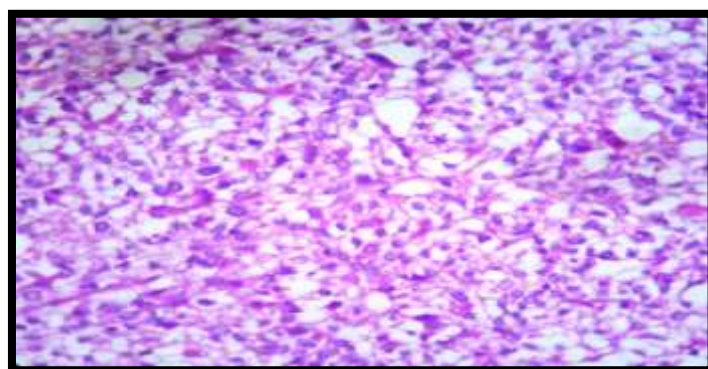
**Figure 4-** External surface showing tumor nodules on mesentery with segment of jejunum



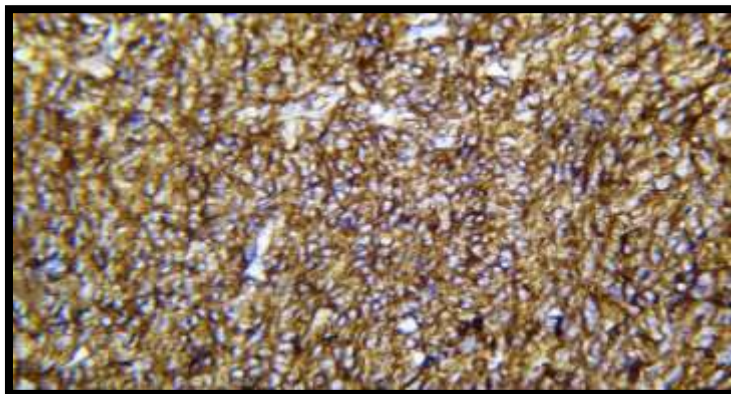
**Figure 5.** Cut section showing well encapsulated, grey white areas, necrosis & hemorrhage



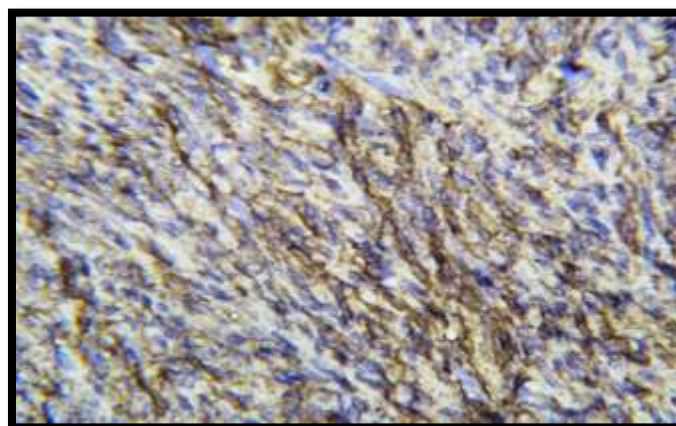
**Figure 6-** Photomicrograph showing spindle cell variant of GIST on H&E, 40x



**Figure.7-** Photomicrograph showing epithelioid variant of GIST on H&E, 40x



**Figure 8A.** Immunohistochemistry showing positivity for CD 117



**Figure 8B.** Immunohistochemistry showing positivity for CD 34

**Table-1 Tumor size**

Tumor size (cm)	Number	Percentage
1-5	5	35.7
6-10	3	21.4
11-15	2	14.2
16-20	3	21.4
>20	1	7.1

**Note:** 3/17 cases; core needle biopsies, size of tumor proper could not be assessed.

**Table -2 Estimated malignancy potential**

Risk of malignancy	No. of case
Very low	0
Low	5 (36%)
Intermediate	3 (21%)
High	6 (43%)

### References

- [1]. Agaram NP, Besmer P, Wong C, Guo Tianhua, Socci ND, et al. Pathologic and molecular heterogeneity in Imatinib-stable or Imatinib-Responsive Gastrointestinal Stromal Tumours. *Clin Cancer Res* 2007; 13(1):170–181.
- [2]. Andtbacka RH, Ng CS, Scaife CL, Cormier JN, Hunt KK, Pisters PW, Pollock RE, Benjamin RS, Burgess MA, Chen LL, Trent J, Patel SR, Raymond K, Feig BW. Surgical resection of gastrointestinal stromal tumours after treatment with imatinib. *Ann Surg Oncol.* 2007 Jan; 14(1):14-24.
- [3]. Mazur MT, Clark HB. Gastric stromal tumours: Reappraisal of histogenesis. *Am J Surg Pathol* 1983; 7: 507–519.
- [4]. Sanders KM, Koh SD, Ward SM. Interstitial cells of Cajal as pacemakers in the gastrointestinal tract. *Annu Rev Physiol.* 2006; 68:307–343.
- [5]. Kim KM, Kang DW, Moon WS, Park JB, Park CK, Sohn JH, Jeong JS, Cho MY, Jin SY, Choi JS, Kang DY; Gastrointestinal Stromal Tumor Committee; Korean Gastrointestinal Pathology Study Group. Gastrointestinal stromal tumours in Koreans: its incidence and the clinical, pathologic and immunohistochemical findings. *J Korean Med Sci.* 2005 Dec; 20(6):977-84
- [6]. Miettinen M, Majidi M, Lasota J. Pathology and diagnostic criteria of GISTs: a review. *Eur J Cancer.* 2002 Sep; 38 Suppl 5:S39-51.
- [7]. Adjuk M, Mikulic D, Sebecic B, Gasparov S et al. Spontaneously ruptured GIST of the jejunum mimicking acute appendicitis. *Coll Antropol.* 2004. 28:937-9418

- [8]. Verweij J,Casali PG,Zalcberg J,LeCesne A,Reichardt P,Blay JY,Issels R,Van Oosterom A,Hogendoorn PC,Van Glabbeke M,Bertulli R,Judson I:Progression-free survival in gastrointestinal stromal tumours with high dose Imatinib: randomized trial. *Lancet* 2004;364: 1127-1134.
- [9]. H. Joensuu Gastrointestinal stromal tumor (GIST). *Ann Oncol.* 2006 Sep; 17 Suppl 10:x 280–6.
- [10]. Joensuu H, Roberts P, Sarlomo-Rikala M et al. Effect of the tyrosine kinase inhibitor STI571 in a patient with metastatic gastrointestinal stromal tumor. *N Engl J Med* 2001; 344: 1052–1056
- [11]. Fletcher CD, Berman JJ, Corless C, Gorstein F, Lasota J, Longley BJ, et al. Diagnosis of gastrointestinal stromal tumours: a consensus approach. *Hum Pathol* 2002;33 (5): 459-65
- [12]. Dei Tos AP. The reappraisal of gastrointestinal stromal tumours: from Stout to the KIT revolution. *Virchows Arch.* 2003 May;442(5):421-8. Epub 2003 Feb 26.
- [13]. Graadt van Roggen JF, van Velthuysen ML, Hogendoorn PC. The histopathological differential diagnosis of gastrointestinal stromal tumours. *J Clin Pathol.* 2001 Feb. 54 (2): 96-102.
- [14]. Nilsson BP, Bummig P, Meis-Kindblom JM, Odén A, Dortok A, Gustavsson B, Sablinska K, Kindblom LG. Gastrointestinal stromal tumours: The incidence, prevalence, clinical course, and prognostication in the preimatinib mesylate era. *Cancer.* 2005 Feb 15; 103(4): 821–9.
- [15]. Goettsch WG, Bos SD, Breekveldt-Postma N, Casparie M, Herings RM, Hogendoorn PC.. Incidence of gastrointestinal stromal tumours is underestimated: Results of a nation-wide study. *Eur J Cancer.* 2005 Dec; 41 (18): 2868–72.
- [16]. Demetri GD, von Mehren M, Antonescu CR, DeMatteo RP, Ganjoo KN, Maki RG, Pisters PW, Raut CP, Riedel RF, Schuetze S, Sundar HM, Trent JC, Wayne JD. NCCN Task Force Report: Update on the management of patients with Gastrointestinal Stromal Tumours. *J Natl Compr Canc Netw.* 2010 Apr;8 Suppl 2:S1-41; quiz S42-4
- [17]. Liegl-Atzwanger B, Fletcher JA, Fletcher CD. Gastrointestinal stromal tumours. *Virchows Arch.* 2010 Feb ;456(2):111-27. doi: 10.1007/s00428-010-0891-y. Epub 2010 Feb 18.
- [18]. Miettinen M, Makhlof H, Sobin LH, Lasota J. Gastrointestinal stromal tumours of the jejunum and ileum: a clinicopathologic, immunohistochemical, and molecular genetic study of 906 cases before imatinib with long-term follow-up. *Am J Surg Pathol.* 2006 Apr ;30 (4): 477-89
- [19]. Fu K, Eloubeidi MA, Jhala NC, Jhala D, Chhieng DC, Eltoum IE.. Diagnosis of gastrointestinal stromal tumor by endoscopic ultrasound-guided fine needle aspiration biopsy--a potential pitfall. *Ann Diagn Pathol.* 2002 Oct;6(5):294-301.
- [20]. Miettinen M, El-Rifai W, H L Sobin L, Lasota J. Evaluation of malignancy and prognosis of gastrointestinal stromal tumours: a review. *Hum Pathol.* 2002 May;33(5):478-83.
- [21]. Kumar R N. Gastrointestinal stromal tumor- a clinicopathological study and its therapeutic outcome in a tertiary care hospital. *Int J Biol Med Res.* 2012; 3(2): 1532-1535.
- [22]. Miettinen M, Sobin LH, Lasota J. Gastrointestinal stromal tumours of the stomach: a clinicopathologic, immunohistochemical, and molecular genetic study of 1765 cases with long-term follow-up. *Am J Surg Pathol* 2005 Jan; 29 (1): 52-68.
- [23]. Dogusoy Bulbul G. (GIST Working Group Turkish Society of Pathology, Turkey Gastrointestinal stromal tumours: Recent results of a nationwide database including 1008 cases with histopathological and immunophenotypical features. 21st European Congress of Pathology. (Oral Presentation), Istanbul. In *Virchows Arch* 2007;451:161.
- [24]. Miettinen M, Lasota J. Gastrointestinal stromal tumours: review on morphology, molecular pathology, prognosis, and differential diagnosis. *Arch Pathol Lab Med* 2006 Oct ; 130 (10) :1466-78.
- [25]. Blay JY, von Mehren M, Blackstein ME. Perspective on updated treatment guidelines for patients with gastrointestinal stromal tumours [review]. *Cancer* 2010;26:1-11
- [26]. Sui XL, Wang H, Sun XW. Expression of DOG1, CD117 and PDGFRA in gastrointestinal stromal tumours and correlations with clinicopathology. *Asian Pac J Cancer Prev* 2012;13:138993
- [27]. Lasota J, Corless CL, Heinrich MC, Debiec-Rychter M, Sciort R, Wardelmann E, et al. Clinicopathologic profile of gastrointestinal stromal tumours (GISTs) with primary KIT exon 13 or exon 17 mutations: a multicenter study on 54 cases. *Mod Pathol* 2008;21:476-84
- [28]. Lev D, Kariv Y, Issakov J, Merhav H, Berger E, Merimsky O, Klausner JM, Gutman M. Gastrointestinal stromal sarcomas. *Br J Surg.* 1999 Apr; 86 (4): 545-9.
- [29]. Dematteo RP, Heinrich MC, El-Rifai WM, Demetri G. Clinical management of gastrointestinal stromal tumours: before and after STI-571. *Hum Pathol.* 2002 May;33(5):466-77.